

EFFECTS OF WHOLE BODY CO-⁶⁰ IRRADIATION ON THE TESTES AND EPIDIDY-
MIDES OF HEDGEHOG (*HEMIECHINUS AURATUS COLLARIS*):
A BIOCHEMICAL ANALYSIS

V.P. DIXIT

*Reproduction Physiology Section, Department of Zoology,
University of Rajasthan, Jaipur-302004*

Summary: The effects of 575 and 875 Rontgen (R) of whole-body irradiation in common Indian hedgehog (*Hemiechinus auratus Collaris*) were studied. At 875 R it showed typical signs and symptoms of radiation sickness, transient body loss and radiation mortality.

Extensive vasculitis, pyknosis, chromatorrhhexis and chromatolysis was noticed in the testes of irradiated hedgehogs. Epididymides and vas deferens were devoid of spermatozoa.

Whole body irradiation inhibited the RNA, protein and sialic acid synthesis in the testes. Total cholesterol per gram of testes was increased significantly. Sialic acid contents of the irradiated epididymides were low.

Reduced androgen production was confirmed in non-active Leydig cells, with diminished sex accessory organs and decreased fructose contents in the seminal vesicles of irradiated hedgehogs.

Key words: Co-⁶⁰ Irradiation testicular degeneration decreased production of RNA
protein and sialic acid vesicular fructose low androgen levels

INTRODUCTION

Extensive studies involving the effects of external, acute or chronic gamma-irradiation on the reproductive function of the laboratory mammals are available (1, 6 and 10). As far as we are aware, no studies have been reported on the testicular function in hibernating mammals following whole body irradiation. Recent atomic implosion in Pokran (Rajasthan), India, stimulated us to study the reproductive physiology of certain mammalian species found in the desert area of Rajasthan. In view of this, it was considered desirable to study the damage caused by Co-⁶⁰ external irradiation, using morphological and biochemical parameters, on the male genital tract of Indian hedgehog (*Hemiechinus auratus Collaris*).

MATERIALS AND METHODS

Twenty four adult male hedgehogs were obtained from the vicinity of Bassi village, near Dausa, Jaipur during March and April, 1975. They were acclimatized in the laboratory for at least 10 days before irradiation. Healthy males weighing 252 ± 15 g were irradiated with 575 R and 875 R using self-contained irradiator containing 5000 Ci Co-⁶⁰ source at an exposure rate of 100R/hour. On day 7 the animals were killed with ether anaesthesia. Final body weight, the weights of testes, seminal vesicles, ventral prostate, epididymides, adrenal and thyroid glands were recorded. Right testes and epididymides were fixed in Bouin's fluid. Six μ m paraffin sections were prepared and stained with haematoxylin and eosin. Left testes, epididymides and seminal

vesicles were frozen and total RNA protein, sialic acid and vesicular fructose were later determined (2, 4 and 12). Quantitative estimation of cholesterol was made according to the Liebermann-Burchard method (5).

One hundred seminiferous tubules appearing circular in section were traced with camera lucida at X 80. Two perpendicular diameters of each tracing were measured, averaged and expressed in terms of mean tubular diameter. Student's t-test was applied in comparing means. The measurements of the diameter of the 100 Leydig cell nuclei were carried out on four sections from each testicle with camera lucida drawings at 800X.

RESULTS

Table I lists average organ weights on day 7 after Co-⁶⁰ whole body irradiation. The weights of the testes show no significant difference within each of the three groups. The weights of seminal vesicles and ventral prostate of 575R treated hedgehogs did not alter, whereas a significant decrease was noticed in 875R treated animals when compared with controls. Weights of adrenal gland increased significantly ($P < 0.01$, Table I) but thyroid gland weights did not change.

In male hedgehogs the testes are permanently intra-abdominal and a scrotum is absent. The spermatogenic cycle is completed in the intra-abdominal testes. The normal seminiferous tubule of the hedgehog contains five to seven layers.

575R

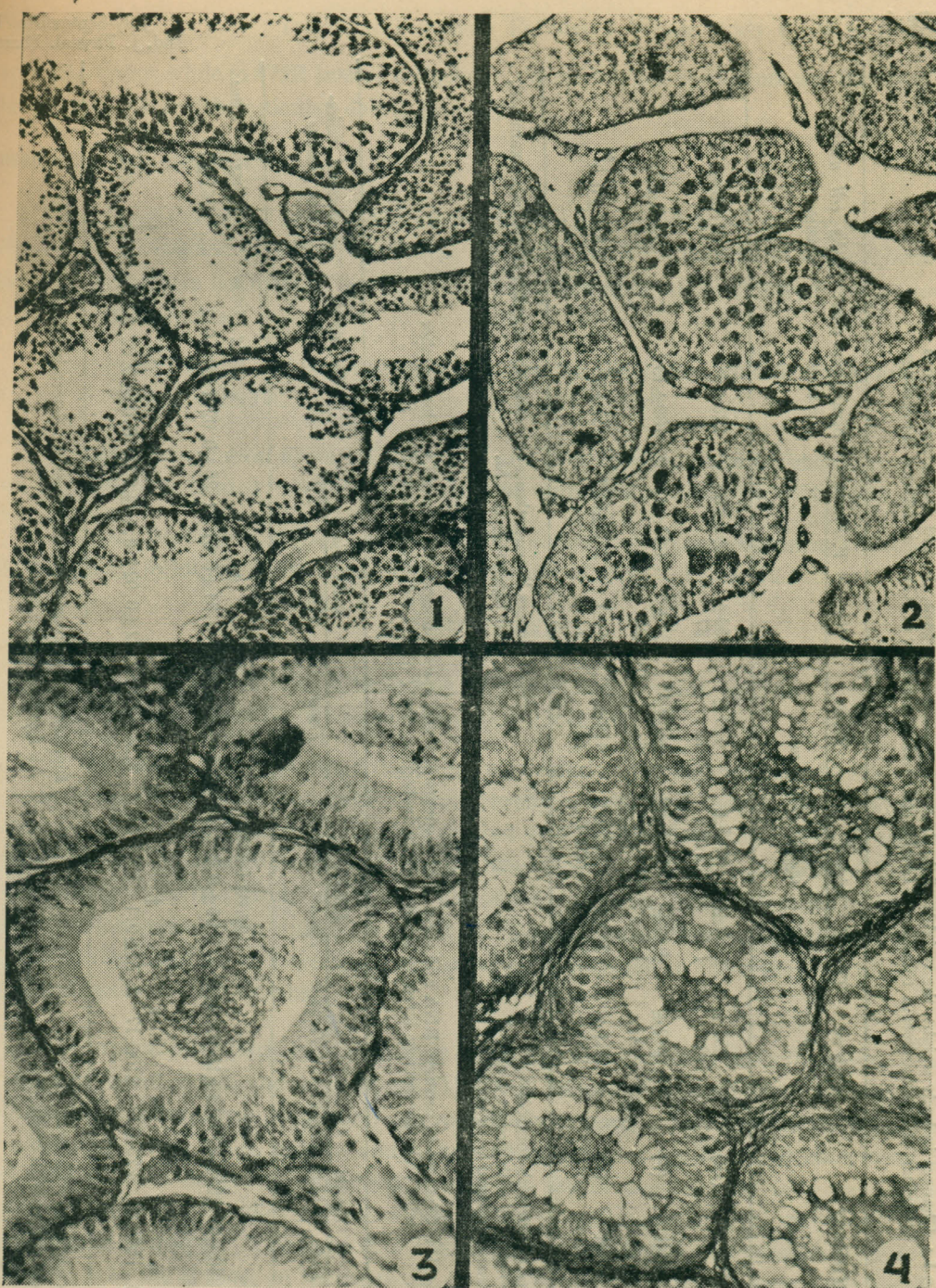
At 7 days interval after irradiation, the median cross sections revealed spermatogonia, spermatocytes and spermatids (Fig. 1). Degeneration, pyknosis and caryorrhexis were seen in spermatogonia and in large spermatocytes. Tubular dimensions were reduced. The Leydig cells were enlarged with abundant cytoplasm.

875R

Fig. 2 shows the effects of Co-⁶⁰ irradiation on day 7 at 875 R. Disappearance and degeneration of many of the spermatogenic cells and small vacuoles enmeshed with fiber lattice were conspicuous. The number of cell layers is frequently two and rarely more than four. Pyknosis, chromatorrhexis and chromatolysis characterize many nuclei. Extensive vasculitis was demonstrated either in one or both testes. There was a greater variation in degree of atrophy manifested by seminiferous tubules and the interstitial tissue. A significant reduction in tubular dimensions and Leydig cell nuclei was noticed (Table I).

EPIDIDYMIDES

The proximal end of the caput epididymides in 575R treated hedgehogs maintained a regular relationship of tubules to each other and to the intervening area and the height of the lining epithelium. The lumen was full of spermatogenic contents (Fig. 3). Neither the distal end of the caput, the corpus nor the cauda epididymides nor the vas deferens showed gross damage to the



- Fig. 1 : Section of a testis from a hedgehog treated with 575R, Co-⁶⁰ gamma rays. Note the testicular lesion. X 80HE.
- Fig. 2 : Section of a testis from a hedgehog treated with a higher dose (875R). Note the severe degenerating tubules. X80, HE.
- Fig. 3 : Section of the caput epididymides (575R), X 160, HE.
- Fig. 4 : Section of the caput epididymides of a hedgehog treated with 875R. The lumen is filled with testicular debris. X 160, H.E.

TABLE I : Changes in body weight, the weights of the testes, accessory sex-organs, thyroid and adrenal glands together with seminiferous tubule and Leydig cell nuclear diameter of Co-⁶⁰ irradiated hedgehogs.

Group	Treatment	Body wt g	mg/100 g body wt			Testes	S. Vesicles	V. Prostate	Seminiferous tubule diameter μ	Leydig cell nuclear diameter μ
			Thyroid	Adrenal						
1.	Control (10)	252 \pm 15	11.5 \pm 1.8	32.5 \pm 2.8	473 \pm 16	935 \pm 137	697 \pm 83	223 \pm 6	11.06 \pm 0.2	
2.	575R (7)	242 \pm 7	9.4 \pm 1.5	54.9 \pm \dagger 5.3	460 \pm ** 47	934 \pm ** 28	667 \pm 125**	180 \pm 13	12.2 \pm 0.7	
3.	875R (7)	251 \pm 21	10.3 \pm 2.0	100 \pm * 21.7	419 \pm 21	534 \pm \dagger 73	256 \pm 39*	251 \pm 9 \dagger	8.3 \pm 0.5 \dagger	

\dagger P<0.01 compared with controls

* P<0.001 compared with group 1 and 2

** Not significant compared with controls

Figures in parentheses represent the number of animals examined,
All figures \pm S.E.M.

TABLE II : Changes in protein, RNA and sialic acid contents of testis, epididymides and seminal vesicles together with vesicular-fructose levels in adult male hedgehog on day 7 after Co-⁶⁰ irradiation (875 R).

	Protein			RNA			Sialic acid			Cholesterol	Seminal vesicular fructose
	Testes	Epid.	S.V.	Testes	Epid.	S.V.	Testes	Epid.	S.V.		
	(μg/mg tissue)									mg/g tissue	μg/mg tissue
Control	330 \pm 43	285 \pm 27	413 \pm 18	3.68 \pm 0.4	1.95 \pm 0.2	2.71 \pm 0.5	0.62 \pm 0.03	0.81 \pm 0.01	1.26 \pm 0.02	1.80 \pm 0.2	265 \pm 15
875R (7 days post-irradiation)	160 \pm 26	225 \pm 39	310 \pm 17	2.75 \pm 0.1	1.30 \pm 0.2	3.50 \pm 0.5	0.52 \pm 0.02*	0.46 \pm 0.01	0.95 \pm 0.02	3.70 \pm 0.05	210 \pm 23*

\dagger P<0.01 compared with controls

*P<0.02 compared with controls

Biochemical estimations : means of six determinations.

All figures \pm S.E.M.

epithelial lining, while in 875R treated hedgehogs, the epididymal epithelium was damaged and the lumen was filled with testicular debris (Fig. 4).

BIOCHEMICAL CHANGES

RNA and protein: Total RNA contents of testes and epididymides were reduced after Co-⁶⁰ whole body irradiation (Table II, $P < 0.01$). Whereas the RNA content of seminal vesicles was elevated, the protein contents of testes, epididymides and seminal vesicles were low as compared with that of controls.

Sialic acid: Sialic acid concentration was low in the testes, epididymides and seminal vesicles of treated animals.

Cholesterol and total lipids: Cholesterol and total lipids/g tissue weight showed a significant increase in the treated testes compared with the untreated controls ($P < 0.01$, Table II).

Seminal vesicular fructose: Mean seminal vesicular fructose concentration was significantly reduced following Co-⁶⁰ whole body irradiation ($P < 0.02$; Table II).

DISCUSSION

Whole body irradiations of hedgehog (875R) showed typical signs and symptoms of radiation sickness, transient body loss and radiation mortality.

In the present investigation, irradiation, particularly with higher dose of 875R, appeared to result in significant accentuation of tubular atrophy in irradiated hedgehogs. Mild regressive tubular lesion was also observed in animals treated with 575R. Extensive vasculitis was noticed in the testes of 875R treated hedgehogs. In the irradiated testes, at 575R, interstitial Leydig cells were numerous and had larger nuclei with abundant cytoplasm, either granular or vacuolated-transformations regarded as due to stimulation. Whereas irradiation with higher dose of 875R resulted in degeneration of Leydig cell nuclei which is reflected in the regression of androgen-dependent accessory sex-organs.

The present histo-pathological findings in the irradiated testes of hedgehogs were generally the same as found in rats and mice (9 and 11). It is important to note that 7 days after whole body irradiation, the sperm production was completely stopped. This was indicated in a decreased concentration of RNA, protein and sialic acid contents of testis. High cholesterol in the testes of irradiated hedgehogs identified this as the site of degenerating cells and fragments. Functional integrity of epididymides is dependent on (a) androgens and (b) spermatozoa and/or testicular fluid (7 and 8). The sialic acid contents of the irradiated epididymides were low, this could be due to the absence of spermatozoa or reduced androgen production. The histological preparations showed the absence of spermatozoa and the presence of testicular debris in the lumen. Reduced androgen production was confirmed in non-active Leydig-cells and decreased fructose contents in the seminal vesicles of irradiated hedgehogs.

REFERENCES

1. Brown, S.O., G.M. Krise, H.B. Pace and J. DeBoer. In: Effect of ionizing radiation on reproductive systems. Eds. W.D. Carlson and F.X. Gassner, p. 103, London, 1964.
2. Lowry, O.H., M.J. Rosebrough, A.L. Fall and R.J. Randall. Protein measurement with the Folin phenol reagent. *J. biol. Chem.*, **193** : 265-275, 1951.
3. Mann, T. Biochemistry of semen and of male reproductive tract, ed. 2. Methuen, London, 1964.
4. Munro, H.N. and A. Fleck. The determination of nucleic acids. In: Methods of biochemical analysis, vol. 14, p. 113, Ed. D. Glick, New York: Interscience, 1966.
5. Oser, B.L. Hawk's physiological chemistry. 14th edn., p. 246, McGraw Hill, New York, 1965.
6. Pace, H.B., G.H. Krise and S.O. Brown. In: The effects of ionizing radiation on the reproductive system. Eds. W.D. Carlson and F.X. Gassner, p. 337, London, 1964.
7. Rajalakshmi, M. and M.R.N. Prasad. Changes in sialic acid in the testes and epididymides of the rat during the onset puberty. *J. Endocr.*, **44** : 379-385, 1969.
8. Rajalakshmi, M. and M.R.N. Prasad. Alterations in sialic acid in the epididymis of the puberal rat in response to changes in functional activity of the testis. *J. Reprod. Fert.*, **24** : 409-413, 1971.
9. Spargo, B., J.R. Bloomfield, D.J. Glotzer, E.L. Gordon and O. Nichols. Histological effects of long-continued whole body gamma irradiation of mice. *J. Natl. Cancer. Inst.*, **12** : 615-655, 1951.
10. Stadler, J. and J.W. Gowen. In: Effects of ionizing radiation on the reproductive system. Eds. W.D. Carlson and F.X. Gassner, p. 111, London, 1964.
11. Warren, S. Effects of radiation on normal tissues. VIII. Effects on the gonads. *Arch. Pathol.*, **35** : 121-131, 1943.
12. Warren, L. The thiobarbituric acid assay of sialic acids. *J. biol. Chem.*, **234** : 1971-1975, 1959.